ARCHIVES
OF
DERMATOLOGY AND SYPHILOLOGY

EDITORIAL BOARD

HOWARD FOX, Chief Editor
140 East Fifty-Fourth Street, New York 22

C. C. DENNIE, Kansas City, Mo.
HAROLD N. COLE, Cleveland
HERBERT RATTNER, Chicago
FRED D. WEIDMAN, Philadelphia
GEORGE M. MacKEE, New York
C. GUY LANE, Boston

VOLUME 49
1944

PUBLISHERS
AMERICAN MEDICAL ASSOCIATION
CHICAGO, ILL.

M

RL1
.A7

1

1023
v. 1

CONTENTS OF VOLUME 49

JANUARY 1944. NUMBER 1

PAGE

Studies on Ointments. Ernest A. Strakosch, M.D., Ph.D., Minneapolis:
VI. Ointments Containing Chrysarobin 1
VII. Zinc Oxide Pastes 8

Calcification and Ossification of Steatomas of the Scrotum: Report of a Case. F. Ronchese, M.D., Providence, R. I. 12

Rational Pharmaceutic Treatment of Diseases of the Skin. Herman Goodman, M.D., New York 16

Dermatologic Significance of Tissue Eosinophilia. Roger J. Burkhart, M.D., and Hamilton Montgomery, M.D., Rochester, Minn. 19

Sulfonamide Compounds in Treatment of Erysipelothrix Rhusiopathiae Infections: Effectiveness of Sulfanilamide, Sulfapyridine, Sulfathiazole and Sulfadiazine Against Experimental Infection in the Mouse and Against Erysipeloid of Rosenbach in Man. Joseph V. Klauder, M.D., and Anna M. Rule, Philadelphia 27

Nutritional Dermatoses in the Rat: X. A Comparison of Disseminated Neurodermatitis and Experimental Magnesium Deficiency. Captain Maurice Sullivan, Medical Corps, Army of the United States, and Virginia J. Evans, Sc.D., Baltimore 33

The Aloe Vera Plant. H. C. Goldberg, M.D., Plainfield, N. J. 46

Severe Erythema Multiforme: Report of Two Cases of the Type Ectodermosis Erosiva Pluriorificialis, with Development of Cicatricial Conjunctivitis and Keratitis in One Case. Walter F. Lever, M.D., Boston 47

Relationship of Balanitis Xerotica Obliterans to Lichen Sclerosus et Atrophicus. Carl W. Laymon, M.D., Minneapolis, and Charles Freeman, M.D., St. Paul 57

Clinical Notes:
Replacement Graft in Surgical Treatment of Lupus Vulgaris. Lester Hollander, M.D., Pittsburgh, and Lieutenant Joseph M. Shelton (MC), U. S. N. R. 60

Abstracts from Current Literature 61

Society Transactions:
New York Dermatological Society 65
New York Academy of Medicine, Section of Dermatology and Syphilis 74
Los Angeles Dermatological Society 79

Book Reviews 86

Directory of Dermatologic Societies 87

FEBRUARY 1944. NUMBER 2

Dermatology in an Army Station Hospital. Lieutenant Colonel Harry W. Woolhandler, Medical Corps, Army of the United States 91

Blood Vitamin A and Cutaneous Diseases. Theodore Cornbleet, M.D.; Hans Popper, M.D., and Frederick Steigmann, M.D., Chicago 103

Ringworm of the Scalp: VI. Successful Use of Roentgen Rays to Epilate Local Areas of Infection. George M. Lewis, M.D., and Mary E. Hopper, M.S., New York 107

Primary Syphilis Treated by Twenty-Six Week Course of Mapharsen and Bismuth: Acute Basilar Meningitis with Neuroretinitis Developing During Treatment. Major Gerard A. De Oreo, Medical Corps, Army of the United States 109

FEBRUARY—*Continued*

PAGE

Association of Lupus Erythematosus and Thyrotoxicosis in Brother and Sister. Erwin P. Zeisler, M.D., and Samuel M. Bluefarb, M.D., Chicago 111

Pemphigus Conjunctivae with Scarring of the Skin: Report of Three Additional Cases. Walter F. Lever, M.D., Boston 113

Balanitis Xerotica Obliterans: Report of a Case. Captain William Leifer, Medical Corps, Army of the United States 118

Epidemiology of Tinea Capitis: I. A Study of Tinea Capitis in a Dispensary. Major Tibor Benedek, Medical Corps, Army of the United States, and I. Myron Felsher, M.D., Chicago 120

Cutaneous Autosensitization: Role of Staphylococci in Chronic Eczema of the Hands. H. Hanford Hopkins, M.D., and E. L. Burky, M.D., Baltimore 124

Chlorophyll Ointment in Treatment of Dermatophytosis of Feet and Similar Lesions. G. I. Wallace, Ph.D.; J. K. Day, M.S., and H. E. Moorman, M.S., Urbana, Ill. 128

Clinical Effects of Paraaminobenzoic Acid in Vitiligo. L. G. Beinhauer, M.D., Pittsburgh 132

American Board of Dermatology and Syphilology: President's Report for 1943 133

Clinical Notes:

Dermatitis Due to Hair Lacquer. Eugene Ostwald, M.D., San Francisco 136

Greenish Pigmentation of Nail Plates from Bacillus Pyocyaneus Infection: Report of Two Cases. Leon Goldman, M.D., and Harry Fox, M.D., Cincinnati 136

Therapeutic Malaria for a Patient Who Had Undergone Splenectomy. Joseph Perlson, M.D., Patton, Calif. 137

Abstracts from Current Literature 138

Society Transactions:

New York Dermatological Society 142

Los Angeles Dermatological Society and San Francisco Dermatological Society 146

New York Academy of Medicine, Section of Dermatology and Syphilis 150

Manhattan Dermatologic Society 152

Book Reviews 156

MARCH 1944. NUMBER 3

Xeroderma Pigmentosum: Report of a Case and Consideration of Incomplete Sex Linkage in Inheritance of the Disease. Madge Thurlow Macklin, M.D., London, Ontario, Canada 157

A Generalized Mercurial (Cinnabar) Reaction Following Tattooing. Lieutenant Commander Frederick G. Novy Jr., MC-V(S), U.S.N.R. 172

Lessened Sensitivity to Tuberculin in Acne. Francis W. Lynch, M.D., St. Paul 174

Neutralization as a Therapeutic Principle in Contact Dermatitis. Nelson Paul Anderson, M.D., Los Angeles 176

Contact Eczema Due to Nail Polish. William L. Dobes, M.D., Atlanta, Ga., and Lieutenant Philip H. Nippert, MC-V(S), U.S.N.R. 183

Clinical Observations on the Use of Soaps Containing an Abrasive. Roy L. Kile, M.D., and Ashton L. Welsh, M.D., Cincinnati 188

Nevus Striatus Symmetricus Unguis: Report of a Case with Involvement of Thumbs and Little Fingers. Edward A. Oliver, M.D., and Samuel M. Bluefarb, M.D., Chicago 190

Dermatitis Due to Shoes. Clarence Shaw, M.D., Chattanooga, Tenn. 191

MARCH—*Continued*

PAGE

American (Mucocutaneous) Leishmaniasis: Observations. Oswaldo G. Costa, M.D., Bello Horizonte, Brazil 194

Clinical Notes:

Contact Dermatitis Due to "Leg Makeup." Francis A. Ellis, M.D., Baltimore 197

An Unusual Example of Dermatitis Due to Nail Polish. John F. Madden, M.D., St. Paul 197

Hair Lacquer Pad Dermatitis. Leon Ginsburg, M.D., and Francis A. Ellis, M.D., Baltimore 198

Replaceable Hagedorn Needle with Handle as Scalpel. Robert P. Little, M.D., Columbus, Ohio 198

Abstracts from Current Literature 199

Society Transactions:

Philadelphia Dermatological Society 202

Brooklyn Dermatological Society 206

Chicago Dermatological Society 212

Editorials:

A Need for More Dermatologists in the War 223

The Campaign Against Leprosy in Cuba 223

Correspondence:

"Rational Pharmaceutic Treatment of Diseases of the Skin." V. Pardo-Castello, M.D., Habana, Cuba 223

Experience of a Dermatologist in the Southern Pacific. Major John V. Ambler, Medical Corps, A. U. S. 224

Book Reviews 225

News and Comment 226

APRIL 1944. NUMBER 4

Behcet's Syndrome with Involvement of the Central Nervous System: Report of a Case, with Necropsy, of Lesions of the Mouth, Genitalia and Eyes; Review of the Literature. Chaim Berlin, M.D., Tel Aviv, Palestine 227

Colloid Degeneration of the Skin: Report of Three Cases from Australia. Lieutenant Eugene A. Hand, MC-V(S), U.S.N.R. 234

Dermatitis Venenata and Keratoconjunctivitis Caused by the Manzanillo Tree. Major James S. Snow and Major R. D. Harley, Medical Corps, Army of the United States 236

Rapid Macroflocculation Test for Syphilis: Method of Rappaport and Eichhorn. E. A. Hewish and Maxwell M. Barritt, M.Sc., D.Bact. L.M.S.S.A., Liverpool, England... 240

Successful Inoculations of Animals with Trichophyton Purpureum: Observations on the Course of the Disease and Immunologic and Histologic Features. Frederick Reiss, M.D., New York 242

Misuse of Sulfonamide Compounds. David Bloom, M.D., New York 249

Calibration of X-Ray Equipment for Superficial Therapy. C. E. Eddy, D.Sc., F.Inst.P., Melbourne, Australia 250

Dermatitis of Eyelids. H. H. Hazen, M.D., Washington, D. C. 253

Keratoderma Climactericum: Cures with Natural and with Synthetic Estrogen. William Garbe, M.D., Toronto, Canada 254

Tuberculin Patch Test and Mantoux Test: Comparative Study in Cases of Various Dermatoses, Including Tuberculoderms. Frances Pascher, M.D., and Marion B. Sulzberger, M.D., New York 256

APRIL—*Continued*

PAGE

Tropical Ulcer. Oswaldo G. Costa, M.D., Bello Horizonte, Brazil 260

Bentonite. Herman Goodman, M.D., New York 264

Dermatitis from Carrots. Samuel M. Peck, M.D., Bethesda, Md.; Louis W. Spolyar, M.D., Indianapolis, and Howard S. Mason, Ph.D., Bethesda, Md 266

Multiple Idiopathic Hemorrhagic Sarcoma of Kaposi in a Full-Blooded Negro. Benjamin P. Persky, M.D., Cleveland, and James R. Lisa, M.D., New York 270

Acrodermatitis Continua (Hallopeau): Effect of Treatment with Sulfapyridine. Walter F. Lever, M.D., Boston 273

Keloids as Sequel to Varicella. Eugene F. Traub, M.D., New York 278

Abstracts from Current Literature 280

Society Transactions:

Chicago Dermatological Society 284

Philadelphia Dermatological Society 287

Los Angeles Dermatological Society 292

Meeting of Civilian and Military Dermatologists Practicing or Serving in Hawaii ... 297

San Francisco Dermatological Society 302

News and Comment 304

Correspondence:

Balanitis Xerotica Obliterans. Fritz B. Reif, M.D., Niagara Falls, N. Y 304

MAY 1944. NUMBER 5

Effectiveness in Vitro of Sulfonamide Compounds on Sporotrichum Schencki: Report of Five Cases of Sporotrichosis in North Carolina. Ray O. Noojin, M.D., and J. Lamar Callaway, M.D., with the Technical Assistance of Judith Killian, A.B., Durham, N. C. . 305

Dermal Myiasis: Report of Three Cases. Lieutenant Colonel John W. Young, Medical Corps, Army of the United States 309

The Asbestos Corn. Lieutenant Commander Herbert S. Alden (MC), U.S.N.R., and Lieutenant William M. Howell (MC), U.S.N.R. 312

Mycosis Fungoides with Bullous Lesions: Special Tests and Laboratory Data Indicating Adrenal Insufficiency. John Garb, M.D., New York 315

Concentration of Arsenic in Blood After Administration of Mapharsen by Rapid Drip Method: Clinical and Experimental Studies. Oswald M. Gruhzit, M.D.; J. A. Sultzaberger, B.S., and Loren W. Shaffer, M.D., Detroit 321

Serum Protein in Dermatoses. William Mulvehill, M.D., Los Angeles 327

Contact Dermatitis Due to Capeweed. Lieutenant Eugene A. Hand, MC-V(S), U.S.N.R. 331

Epidermolysis Bullosa. Major Samuel I. Greenberg, Medical Corps, Army of the United States 333

Asymmetric Cutaneous Lesions in Pellagra. Major William Bennett Bean, Medical Corps, Army of the United States, and Tom Douglas Spies, M.D., and Richard W. Vilter, M.D., Cincinnati 335

Area Factor in Roentgen Irradiation. H. C. Goldberg, M.D., Plainfield, N. J 346

Treatment of Erysipeloid by Cryotherapy. Culver M. Griswold, M.D., and Shirley S. Bowen, M.D., Houston, Texas 348

Papulonecrotic Tuberculid in the Negro: Its Clinical Resemblance to Acne Vulgaris and Early Syphilids. S. Irgang, M.D., New York 351

MAY—*Continued*

PAGE

Clinical Notes:

Lupus Erythematosus with False Positive Kahn Reactions. Lieutenant Commander Lauren Sompayrac (MC), U.S.N.R., and Lieutenant Commander Hugh E. Hailey (MC), U.S.N.R. 355

Acid Orcein–Giemsa Stain (Modification of Unna-Taenzer Method): A Useful Routine Stain for Dermatologic Sections. Hermann Pinkus, M.D., Monroe, Mich. 355

Correspondence:

Chick Embryo Antigen Test for Lymphogranuloma Venereum. Harold N. Cole, M.D., Cleveland 357

Alibour's Water. Robert P. Little, M.D., New York 357

Abstracts from Current Literature 358

Society Transactions:

Atlantic Dermatologic Conference 362

New York Academy of Medicine, Section of Dermatology and Syphilis 374

Philadelphia Dermatological Society 381

Manhattan Dermatologic Society 385

Book Reviews 388

JUNE 1944. NUMBER 6

Keratosis Blennorrhagica Without Gonorrhea (Reiter's Disease?). Walter F. Lever, M.D., and G. Marshall Crawford, M.D., Boston 389

Chromoblastomycosis: Report of a Case from Continental United States and Discussion of the Classification of the Causative Fungus. Chapman H. Binford, M.D., New Orleans, and George Hess, M.D., Atlanta, Ga., with Mycologic Report and Discussion by C. W. Emmons, Ph.D., Washington, D. C. 398

Intensive Ambulatory Therapy of Syphilis: Thirty Day Mapharsen Technic. Major Samuel Goldblatt, Medical Corps, Army of the United States 403

Ulcerative Diphtheria of the Skin: Sporadic and Epidemic Types Observed in Haifa, Palestine. S. Gill, M.D., Haifa, Palestine 408

Hereditary Ectodermal Dysplasia: Report of a Case, with Experimental Study. Zachary Felsher, M.D., Chicago 410

Localized Myxedema in Association with Hyperthyroidism. Joseph C. Amersbach, M.D., and Ben Kanee, M.D., New York 415

Fixed Erythema Due to Sulfanilamide with Gradually Lessening Sensitivity. A. Dostrovski, M.D., and F. Sagher, M.D., Jerusalem, Palestine 418

Coal Tar in Dermatologic Preparations. J. G. Downing, M.D.; L. M. Ohmart, A.M., and G. Di Cicco, B.S., Boston 421

Bullous Lichen Sclerosus et Atrophicus: Its Relation to Bullous Scleroderma. C. Russell Anderson, M.D., Los Angeles 423

Cutaneous Absorption: II. The Value of Petrolatum, Anhydrous Wool Fat and Other Bases in Percutaneous Absorption of Topically Applied Cottonseed Allergen. Abraham Walzer, M.D., and Samuel S. Sack, M.D., Brooklyn 427

Contact Dermatitis from Cold Permanent Waving. J. B. Howell, M.D., Dallas, Texas 432

Cutaneous Leishmaniasis (Oriental Sore): I. Time Required for Development of Immunity After Vaccination. D. A. Berberian, M.D., Beirut, Lebanon 433

Clinical Notes:

Microsporon Audouini Infection of the Eyelashes. Seymour H. Silvers, M.D., Brooklyn 436

A New Protective Cream. J. G. Downing, M.D.; L. M. Ohmart, A.M., and M. J. Stoklosa, B.S., Boston 436

Gonorrhea of the Skin. H. J. Templeton, M.D., Oakland, Calif. 436

JUNE—*Continued*

PAGE

Dermatologists of the United States and Canada in Active Service in the Present War.... 437

Abstracts from Current Literature.... 441

Society Transactions:

Cleveland Dermatological Society.... 446

Minnesota Dermatological Society.... 449

Los Angeles Dermatological Society.... 453

Book Reviews.... 460

General Index.... 461

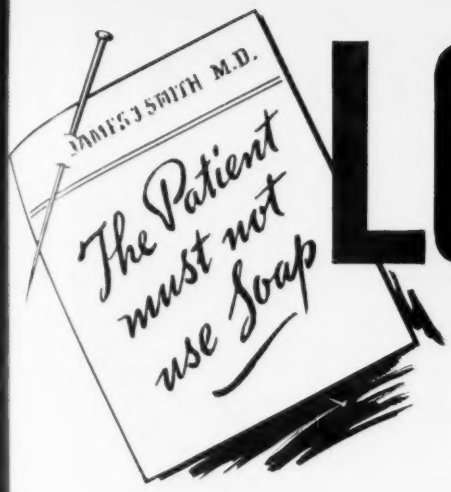

LOWILA

A SOAPLESS DETERGENT IN CONVENIENT CAKE FORM

LOWILA CAKE contains lauryl sulfoacetate diluted in bentonite. The pH approximates that of normal skin (pH 5.0 to 5.5)—it is free of all perfume.

•

LOWILA CAKE is non-irritating, only mildly defatting and of low sensitizing index; cleanses the skin as satisfactorily as soap—at a cost comparable to that of soap.

•

LOWILA CAKE is an excellent cleanser for general toilet use—including the bath and shaving.

•

SUGGESTED as a SOAP SUBSTITUTE in all conditions due to or aggravated by the use of soap and allied cleansers.

Lowila Supplies
Soft, Creamy Suds

Please Fill In, Clip, and Mail Coupon for Liberal Trial Supply

WESTWOOD PHARMACAL CORP.
1020 Main St., Buffalo 2, N. Y.

Send Lowila Cake for Clinical Trial

(PLEASE PRINT NAME AND ADDRESS) ..... M.D.

.....

.....

Westwood Pharmacal Corp.

1020 MAIN ST., BUFFALO 2, N. Y.

WASSERMANN FASTNESS

(SERORESISTANT SYPHILIS)

"Seroresistance is associated with a high proportion (about 40 per cent), of asymptomatic neurosyphilis."

Management of Syphilis in General Practice, U.S.P.H.S. Supp. No. 6 to Venereal Disease Information p. 60, Oct. 1939.

In every instance of seroresistance in early syphilis, the spinal fluid of the patient should be examined or re-examined as the case may be. Disclosure of involvement of the cerebrospinal axis indicates that this may be the cause of the seroresistance.

Tryparsamide Merck has an unusual power of therapeutic penetration in case of the central nervous system. Consideration of the employment of Tryparsamide Merck is suggested in the treatment of all patients with neurosyphilis.

MERCK & CO., Inc. *Manufacturing Chemists* RAHWAY, N. J.

Tell-tale!

Certainly no careful syphilologist needs to be reminded that he must proceed with the utmost caution when called upon to treat cardiovascular and hepatic syphilis and syphilis in elderly persons. In such cases, he knows that a *milder* course of treatment is often necessary or the results may be disastrous. That's why many employ Bismarsen when the routine antisyphilitic drugs are contraindicated. This exclusive Abbott product, containing 13% arsenic and 23% bismuth, exerts a *slow* yet pronounced spirillicidal action. It rarely produces therapeutic shock or Herxheimer reactions when the initial dose is small. It is well tolerated in relatively high doses by children and elderly persons, and seldom causes jaundice, renal irritation, gastrointestinal disturbances, fever, headache or cerebral accident. Bismarsen is injected *intramuscularly*—a definite advantage in those cases where intravenous therapy is impractical or contraindicated as in infants, children and obese patients. You may obtain Bismarsen through Abbott - D-R-L distributors in 0.1-Gm. and 0.2-Gm. ampoules, with a special solvent (a weak aqueous solution of Butyn Sulfate). Complete literature upon request. Abbott Laboratories, North Chicago, Ill.

Bismarsen

REG. U. S. PAT. OFF.

BISMUTH ARSPHENAMINE SULFONATE, D-R-L

Sensitive Chapped Skin

YOUR patients who have sensitive skins especially affected by chapping during the winter months may need emollient creams and lotions to help restore oils lost through exposure. Marcelle hypo-allergenic Cosmetics has a generous assortment of beauty aids for sensitive, chapped skin.

Known irritants have either been removed or reduced to a minimum in the production of Marcelle hypo-allergenic Cosmetics. An increasing number of physicians have been recommending Marcelle hypo-allergenic Cosmetics for patients with sensitive skins, and as a routine precaution in many skin disorders. You can prescribe them with confidence.

Marcelle hypo-allergenic Cosmetics have been accepted for advertising in publications of the American Medical Association for 12 years.

Marcelle
HYPO-ALLERGENIC
COSMETICS

Write for professional samples and a formulary booklet specifying ingredients of Marcelle Cosmetics. This offer is not good in Canada.

MARCELLE COSMETICS
1741 North Western Ave., Chicago 47, Illinois

A RICH source of the vitamins of the B-complex, VioBin may advantageously supplement the diet in skin disorders in which dietary deficiencies are suspected.*

In *high protein — low-fat* diets VioBin presents a rich source of biologically adequate protein (40%). One ounce affords the total daily requirement of vitamin B_1, a goodly portion of that of the other components of the B-complex, one-sixth the requirement of protein, one-third that of iron, and two-fifths that of phosphorus. VioBin is defatted, partially dehydrated wheat germ. Since it is defatted, it yields only 3.5 calories per gram; is perfectly stable; requires no refrigeration. . . . The VioBin Corporation, Monticello, Ill.

*Gross, P., and Kesten, B.: Treatment of Psoriasis with Lipotropic Substances from Foodstuffs, Arch. Dermat. & Syph. 47:159 (Feb.) 1943.

VioBin

Analysis

	%
Moisture	7.0%
Total solids	93.0%
Protein (N x 6.25)	39.0%
Crude Fiber	2.0%
Carbohydrates other than crude fiber (by difference) (N. Free extract)	46.15%
Fat (ether extract)	0.85%
Total Ash	5.00%

Minerals

	IN ASH
Potassium as K	1.1 %
Calcium as Ca	0.067 %
Magnesium as Mg	0.353 %
Phosphorus as P	1.100 %
Manganese as Mn	0.009 %
Copper as Cu	0.0014%
Iron as Fe	0.011 %

Vitamins

	PER GRAM
Thiamine	33 gamma
Riboflavin	8 gamma
Nicotinic acid	69 gamma
Pyridoxine	15 gamma
Pantothenic acid	35 gamma
Inositol	2.5 mg.
Biotin	452 milligamma

Added to the average diet in the numerous ways to which it lends itself, VioBin (2 tbsp. daily) can well bring the intake of essential nutrients to optimum levels.

IS THERE A DOCTOR'S WIFE IN THE HOUSE?



We've a message — and a gift — for your wife. We want her to try our preparations. It will take about an hour of her time, and in return for that courtesy we will present her with a Beauty Counselor $1.00 lipstick in any shade she selects.

We believe she will enjoy the hour. But, most important, we hope she will tell *you* about our *try-before-you-buy* method of selection—how each customer has a chance to use these hypo-allergenic preparations, without charge, to see that those recommended really suit her skin.

Please use the coupon below. If, in addition, you would be interested to see formulas, check where indicated.

beauty counselors

beauty counselors, inc., 17108 Mack Avenue, Grosse Pointe, Michigan

☐ Send me formulas.

☐ Arrange to give my wife a presentation and a $1.00 lipstick. You will find her at home at

Street_____ City_____ Phone_____

Doctor_____ Address_____

A.D.S.

FIRST CHOICE BY ACTUAL VOTE

Recently, an impartial, nation-wide survey was conducted among the Dermatologists of America* to determine which Lather-type Shave Cream you prefer for personal use. Mennen Lather Shave received more votes than any other brand.

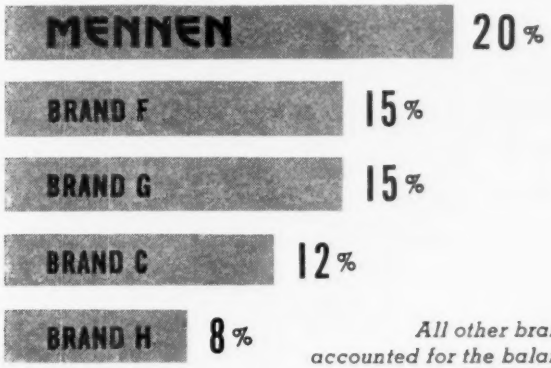

All other brands accounted for the balance

This decisive preference for Mennen Lather Shave is professional recognition of the high standards of quality Mennen has maintained for over half a century.

*Official A. M. A. Roster

MENNEN

For Surgical Antisepsis

Zephiran Chloride is a germicide of high bactericidal and bacteriostatic potency. In proper dilutions it is nonirritating and relatively nontoxic to tissue cells.

Zephiran Chloride possesses detergent, keratolytic and emulsifying properties, which favor penetration of tissue surfaces, hence removing dirt, skin fats and desquamating skin.

INDICATIONS

Zephiran Chloride is widely employed for skin and mucous membrane antisepsis—for preoperative disinfection of skin, denuded skin and mucous membranes, for vaginal instillation and irrigation, for vesical and urethral irrigation, for wet dressings, for irrigation in eye, ear, nose and throat infections, etc.

ACCEPTED AMERICAN MEDICAL ASSN.

HOW SUPPLIED

Zephiran Chloride is available in

TINCTURE 1:1000 Tinted

TINCTURE 1:1000 Stainless

AQUEOUS SOLUTION 1:1000

in 8 ounce and 1 gallon bottles.

Write for informative booklet

ZEPHIRAN
Trademark Reg. U. S. Pat. Off. & Canada
CHLORIDE
Brand of BENZALKONIUM CHLORIDE

ARMY E NAVY

WINTHROP CHEMICAL COMPANY, INC.

NEW YORK 13, N. Y. *Pharmaceuticals of merit for the physician* WINDSOR, ONT.

WINTHROP